


Original Research Article

MRI is the gold standard investigation for early detection, extent of involvement and management of patient in Pott's spine

Anil Rathva¹, Siddharth Zala^{2*}

¹Assistant Professor, ²PG Student,
SBKS MI & RC, Sumandeep Vidyapeeth, Vadodara, Gujarat, India

*Corresponding author email: siddharth.zala@gmail.com

	International Archives of Integrated Medicine, Vol. 4, Issue 1, January, 2017. Copy right © 2017, IAIM, All Rights Reserved. Available online at http://iaimjournal.com/	
	ISSN: 2394-0026 (P)	ISSN: 2394-0034 (O)
	Received on: 21-12-2016 Source of support: Nil	Accepted on: 30-12-2016 Conflict of interest: None declared.
How to cite this article: Rathva A, Zala S. MRI is the gold standard investigation for early detection, extent of involvement and management of patient in Pott's spine. IAIM, 2017; 4(1): 7-15.		

Abstract

Introduction: Tuberculosis is increasing in the developing countries and re-emerging in the developed ones because of overcrowding and increase in of population. Spinal TB is the most clinically important form of extra-pulmonary tuberculosis, as it may produce serious neurological sequel due to compression of spinal cord by its excessive spread and involvement of spinal canal as a result of the disease itself, as well as the resultant deformity. Early recognition and prompt treatment are therefore necessary to minimize residual spinal deformity and or permanent neurological deficit. This retrospective study lightens and correlates the image morphology of spinal TB on MRI.

Materials and methods: The study was done from January 2015 to June 2015 on 70 patients diagnosed with Tuberculosis of spine. MRI of spine was carried out in all the patients. MRI was done using a 1.5 tesla Philips system. MRI features were observed on T1W, T2W, Short tau inversion recovery (STIR) and post contrast (gadolinium) T1W sequences with sections in sagittal, coronal and axial planes.

Results: This study showed that the most common clinical feature was back pain followed by deformity with most patients being afebrile. Most common vertebrae involved were dorsal followed by lumbar and the cervical with sacral being the least involved. Central type of vertebral lesion was common than paradiscal and rarely it involves posterior elements and inter vertebral disc. As compared to the other modalities soft tissue involvement, extent of lesion, type of lesion and Inter vertebral disc involvement are better visualised on MRI.

Conclusion: MRI offers excellent visualization of the bone and soft tissue components of spinal tuberculosis and helps to identify disease at distant asymptomatic sites (skip lesions) before and accurately as compare to other modalities. MR imaging clearly demonstrated the extent of soft tissue

involvement and its effect on the thecal sac/cord and neural foramen. It helps in early diagnosis and therefore management.

Key words

MRI, Gold standard, Pott's spine.

Introduction

A tubercular infection of the spine or tubercular spondylitis or Pott's disease was first described by Percival Pott in 1779 and it has been detected in the ancient mummies in Egypt and Peru. It is caused by the *Mycobacterium tuberculosis* the way of spread of these bacteria is most commonly by a hematogenous spread of [1] via the venous plexus of Batson [2]. According to the World Health Organization, in 2006, nearly 2 billion people, about 1/3rd of the world's population had tuberculosis and it has been reported that annually 6 million become ill and 2 million die from this disease worldwide. It remains the prime infection which causes high morbidity and mortality in the densely populated developing countries. The incidence of tuberculosis had declined in the western world, but in recent years, it has shown resurgence in these non-endemic populations where the socio-economic condition is poor. There has also been an increase in its global prevalence because of overcrowding, particularly in immunocompromised patients, with a rate of increase of approximately 1.1% per year [2]. The main causes of the increase in the occurrence of tuberculosis worldwide, appears to be the Human Immunodeficiency Virus (HIV) epidemic, poor nutrition, drug addiction, alcoholism, appearance of the drug-resistant strains of tuberculosis, ineffective tuberculosis control programs, overcrowding and increased migration from endemic areas to non endemic areas [3, 4]. About 10.7 million people worldwide have both the HIV and the tuberculosis infections. The occurrence of tuberculosis is thus closely related to epidemiologically sensitive parameters and these parameters can alter the occurrence of various pathological processes of tuberculosis. The infectious process in the vertebral body spread usually starts in the cancellous bone of the

vertebral body, anteriorly under the periosteum, later extending to the inter vertebral disc and to other parts of vertebrae. The destructive process which involves the bone leads to a collapse of the body of the vertebra, along with its wedging. Secondary to infective process immune response causes the formation of granulation tissue and necrotic material and collect within the lytic areas of the bone and in the surrounding soft tissue planes and this infective process can extend directly into the psoas muscle, leading to an abscess formation. The presenting symptoms of Pott's spine include low-grade fever with an evening rise, lethargy, malaise, night sweats, anorexia and weight loss, which are common to any tubercular infection which helps in clinical diagnosis [4]. The symptoms which are characteristic of Pott's spine consist of local tenderness and limitations of the motion and in the late phases of the disease, severe spinal deformity in form of gibbus deformity may happen. The worst complications of tuberculosis of the spine are paresis or paralysis depends on which level it involves quadriplegia, hemiplegia or monoplegia can occur [4]. Tuberculosis is the most common cause of non-traumatic paraplegia in the most parts of world [4, 5]. The neurological symptoms tend to occur in the acute as well as the late stages of the disease so early diagnosis can help the patient to go in to the complication of Pott's spine. The neurological symptoms in tuberculous spine include radicular pain, the severe cauda equina syndrome and spinal cord compression. They may result from edema, vascular engorgement, vertebral collapse, retracted debris, meningomyelitis or subarachnoid collections [3]. The multi-planar images and the better tissue contrast with different sequences make MR imaging the modality of choice in the evaluation and the follow-up of Pott's spine [2]. It shows not only a

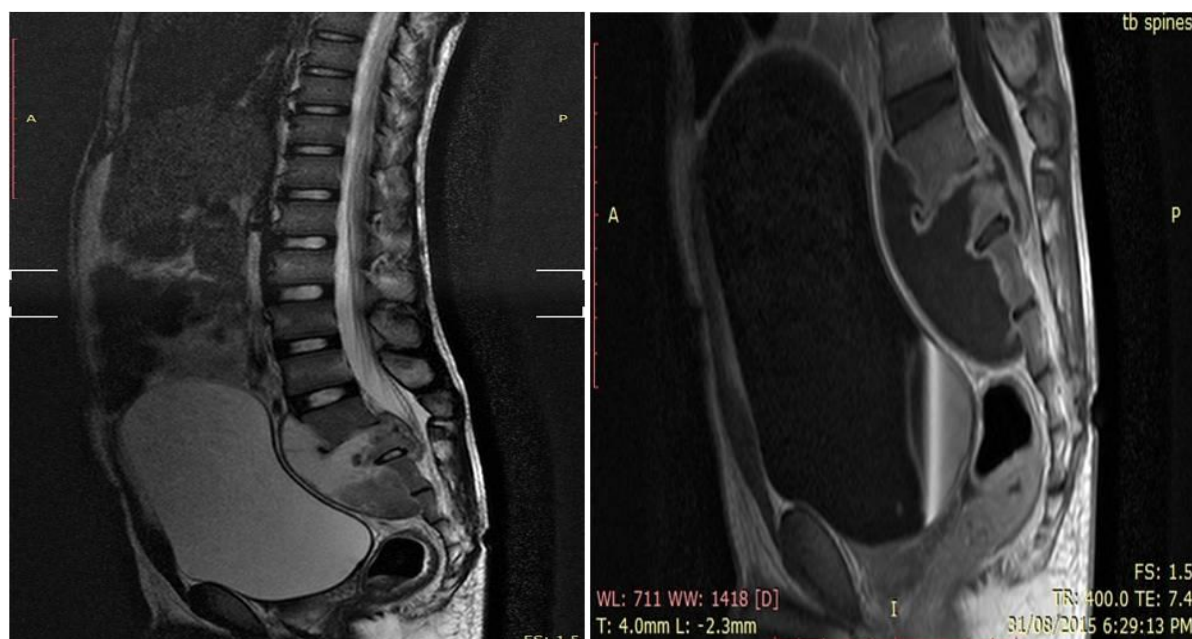bony involvement but helps to assess response to the treatment. Despite its advantages, one of the greatest limitations of MRI is its inability to identify the soft tissue calcification involving pre and para spinous soft tissue and psoas muscles on the routine scans, which is characteristic of the tubercular infection. Moreover, it is difficult to perform a guided percutaneous aspiration and a biopsy of the lesion on an MRI scanner. The MRI appearance of tuberculosis mimics various other pathological processes and these can be categorized into infectious and neoplastic lesions. The major differential diagnoses include low grade infections like atypical mycobacteria, brucella and fungal infections and neoplasms like lymphomas, multiple myelomas and metastases. These infections generally involve the inter vertebral discs where as in neoplasm it spared to the adjacent bony as well as soft tissue [3].

Materials and methods

The aim of this study was to understand the pattern of occurrence and to analyze the various pathological processes of Pott's spine by using

the MRI scan. This study was done at Dhiraj General Hospital, SBKS MI & RC, Waghodiya, Vadodara, Gujarat, India which predominantly caters to the rural population. MRI scans of all the proven cases of Pott's spine, which were done in the Department of Radiodiagnosis from January 2015 to June 2015, were retrospectively studied. This study included 70 cases in which tuberculosis was histopathologically proven either before the MRI scan or after a suspicion of Pott's spine was raised following the scan. The patients of all age groups and both sexes were included in the study, while repeat scans of the same patient were excluded. The scans were done on a 1.5T Philips scanner by using T1 Weighted spin echo (T1W) and T2 weighted fast spin echo (T2W) sequences in the sagittal and the axial planes and a fat Suppressed Inversion Recovery (STIR) sequence in the coronal plane. The bony structures were identified and any collapse or destruction which was characterized as a hyperintensity on the T2W sequence and as a hypointensity on the T1W sequence was noted (**Figure – 1**).

Figure - 1: T2W (A) and T1W post contrast (B) images in sagittal plane showing destruction and erosion of end plates of L5 to S3 vertebral bodies with involvement of respective IVDS disc, prevertebral and epidural collection causing neural compression and narrowing of spinal canal. The necrotic component of epidural and prevertebral soft tissue collection appears hyper intense on T2 and (A) with peripheral enhancement on post contrast T1W sequence with involved vertebral body enhancement.



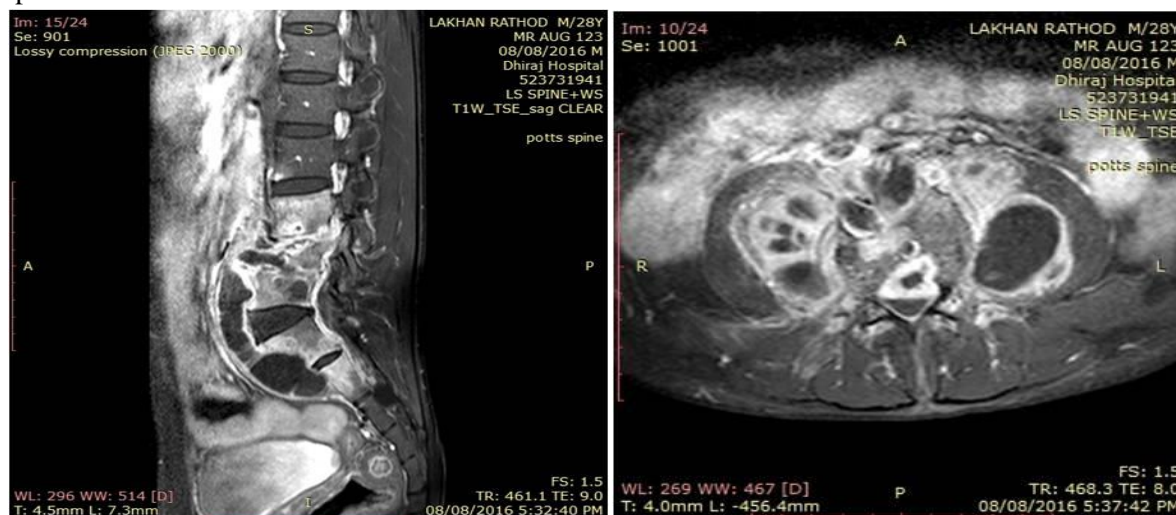
The marrow edema appeared as a low signal on the T1W sequence and as a hyper intensity on the STIR sequence. The posterior margins of the vertebral bodies were viewed in detail for any posterior displacement or a bony fragment in the epidural space. The CSF column was traced for any collection in the epidural space, which appeared as a hypointensity on the T1W sequence with heterogeneity, suggesting the presence of necrotic material and granulation tissue which caused elevation of the dura and compromise of the subarachnoid space. The extent of this collection was noted and more than a 75% reduction in the thickness of the CSF column was considered as significant and as causing neural compression (**Figure – 2**).

A similar collection in the pre/paravertebral planes and in the psoas muscles suggested an abscess and screening of the whole spine was done to identify the skip lesions (**Figures - 3A** and **Figure - 3B**). The posterior bony component

was meticulously visualized for the presence of marrow oedema or destruction (**Figure - 3C**).

The cord edema was identified as a hyperintensity on the T2W sequence and an alteration in the curvature was noted (**Figure – 2**). Tuberculosis is characteristically associated with little or no reactive sclerosis or local periosteal reaction, a feature that helps in distinguishing it from pyogenic infections of the spine [2]. A CT or ultrasound guided aspiration of the paravertebral collection or the pathological bony tissue was obtained and sent for culture. The sample was also histopathologically examined for caseating granulomas, along with the detection of acid fast bacilli on Ziehl Neelsen's staining [3]. If the above investigations were negative, we excluded such cases from our study. The major limitation of the pathological examination is that in many cases of tuberculosis, the above findings are absent and in such cases, the polymerase chain reaction could be positive.

Figure - 2: T1W sagittal (A) and T1 axial (B) post contrast sequence images showing destructive lesion involving L3 to S2 vertebral bodies with also involvement of bilateral psoas muscle and pre spinous soft tissue.



Results

70 cases of Pott's spine were included in this study, out of which 39 (55.7%) were males. 31 (44.28%) patients were between 21 to 40 years of age with a female predominance, while 45

(64.2%) cases were in the age group of 21 to 50 years (**Table – 1**).

Multiple vertebrae were affected in most of the cases and a majority had 2 vertebrae involved (60%), followed by the involvement of 3-4

vertebrae (25%), while a single case had a single vertebra involved (**Figure – 4**).

In 37 (52.8%) cases, the dorsal and in 43 (61.4%) cases, the lumbar vertebrae were involved. Among these, 12 cases had both the dorsal and

the lumbar vertebrae involvement. Two cases of dorsal vertebrae involvement were in association with the cervical vertebrae and 1 case of the lumbar vertebra was involved in association with the sacrum (**Figure – 5**).

Figure - 3: Post contrast T1W images (A) sagittal image shows erosion and destruction of D11 and D12 vertebrae with reduced vertebral body height with preserved IVDS. (B) axial (c) coronal images shows pre and bilateral para spinous soft tissue involvement.

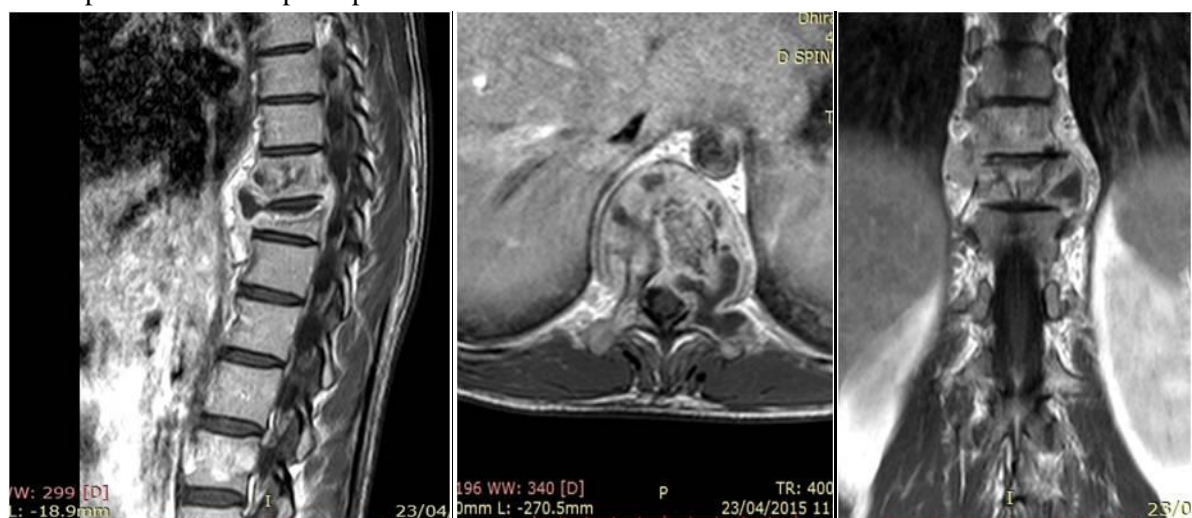

Table – 1: Age and sex distribution of cases of tubercular spondylitis.

Age (Years)	≤10	11-20	21-30	31-40	41-50	51-60	61-70	>71	Total
Male	3	4	7	7	9	4	8	2	44
Female	-	3	13	8	7	3	-	2	36
Total	3	7	20	15	16	7	8	4	80

Figure - 4: Bar chart showing distribution of number of cases and number of vertebrae infected.

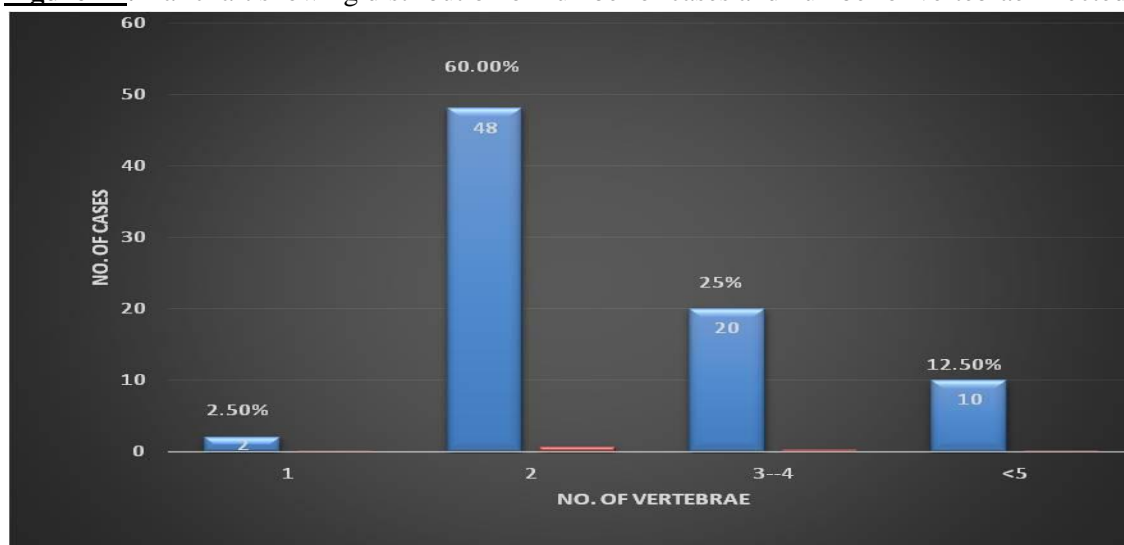


Figure - 5: Venn chart showing pattern of involvement of various segments of spine.

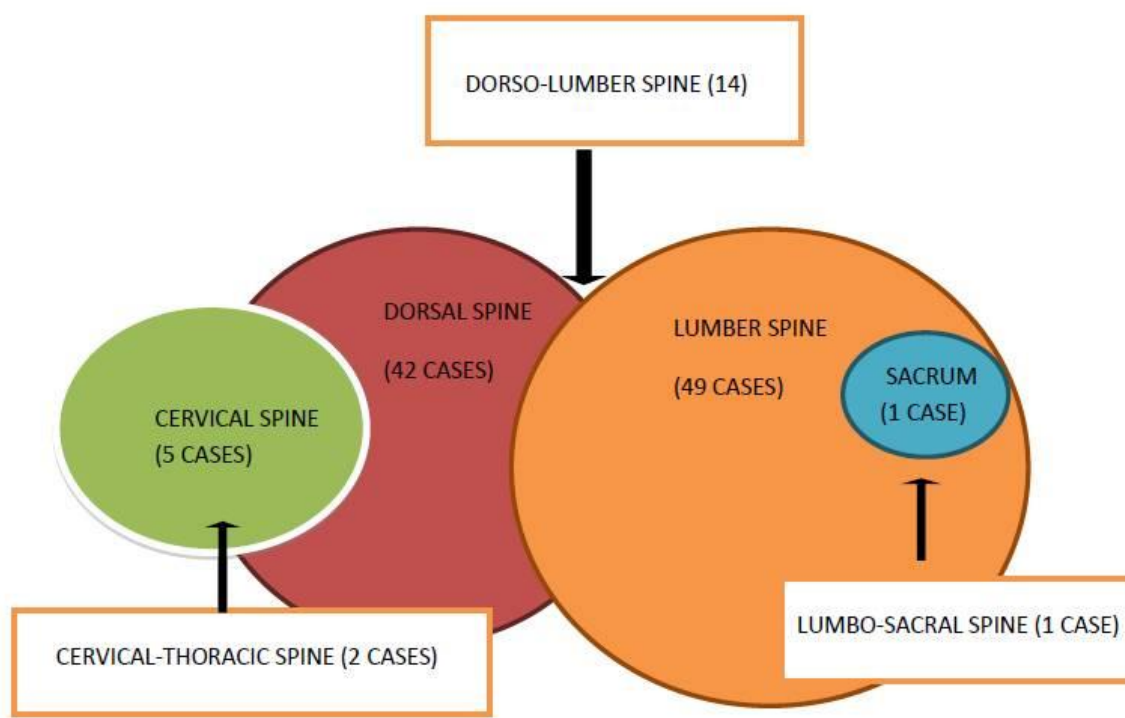
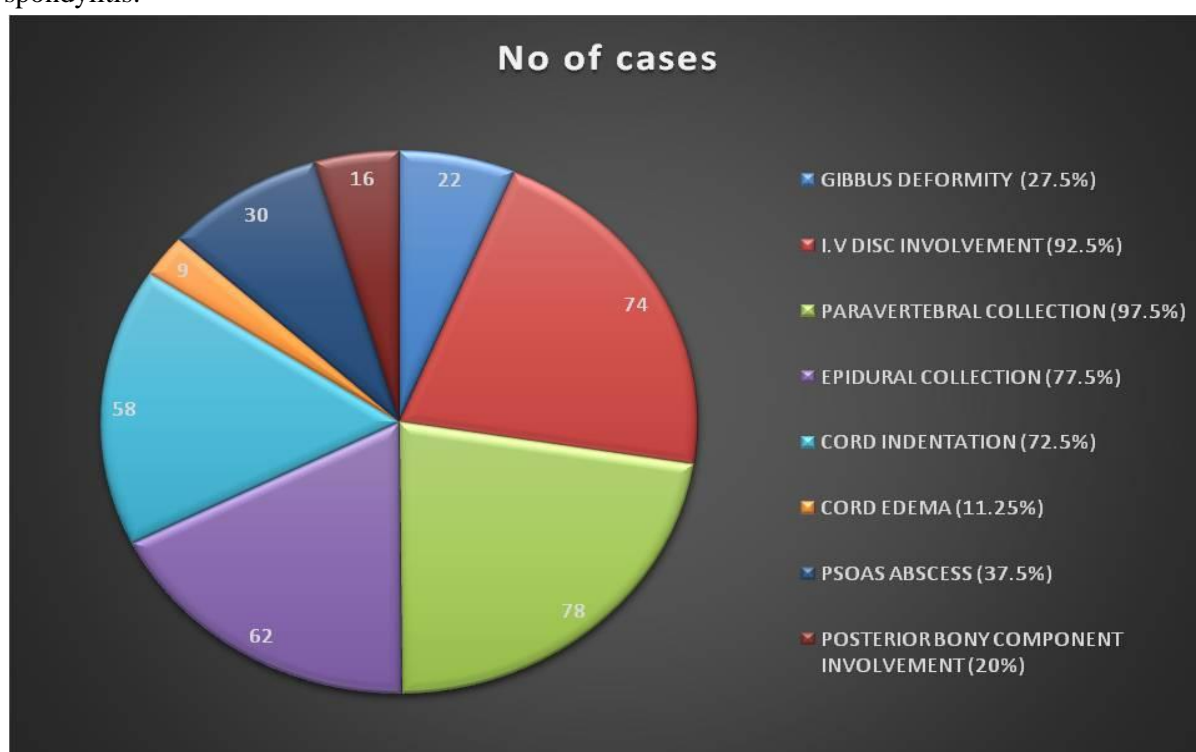


Figure - 6: Pie chart showing pattern of occurrence of various pathological processes of tubercular spondylitis.



The cervical vertebrae were involved in a total of 4 cases, out of which 3 cases were below 30 years of age. Skip lesions were noted in 2 (2.85%) cases. The vertebral body which was

affected in a majority of the cases was L3 (34.2%). An alteration in the curvature, mostly a gibbus deformity which was due to the collapse of the vertebrae was noted in 19 (27.2%) cases.

An intervertebral disc involvement was a common finding which was noted in 65 (92.8%) cases. A pre or paravertebral collection was seen in all cases except 1 case (98.5%), while an epidural collection was present in 58 (82.9%) cases (**Figure – 6**).

This epidural collection caused thecal sac indentation in 51 cases, while a cord compromise which was due to a gibbus deformity or posteriorly displaced bony fragments was noted in 16 cases. The combination of the gibbus and the epidural collections caused a neural compromise in 14 patients. The canal dimension was reduced by 75%, which was considered as severe.

A neural compromise was noted in 15 (21.4%) cases. Cord edema was appreciated in 7 (10%) cases. The Psoas abscess was noted in 26 (37.4%) cases, among which a bilateral involvement was seen in 10 patients. Among the 16 cases with the unilateral psoas abscess, 9 were on the right side and 7 were on the left side. The marrow edema or the destructive process extended into the posterior bony components in 13 (18.6%) cases, among which 11 had involvement of the pedicle.

Discussion

Tuberculosis of the skeletal system constitutes 1-5 % cases of tuberculosis, out of which 50% have vertebral column involvement [6]. Osborn [7] stated that in the developing countries it was prevalent in the younger age group, while in the western world, it was found in the middle age (mean 40-45 years). Sinan, et al. [8] found 43% cases in their study in the age group of 30-49 years. In our study, most of the cases were between the ages of 21-50 years (mean 38.3 + 17.6), which was similar to the finding of Mirsaiedi, et al. [9] who found a mean age of 39 + 16 years. Tuberculosis of the spine was found to be more common in males than in females in most of the previously published series [4,8-10], although Osborn [7] suggested no gender predilection. We noted that although overall

Pott's spine was more prevalent in males, in between 21-50 years of age in which Pott's spine was the most prevalent, there was a female predominance (55%). In the 21-30 year age group, 66.6% of the patients were females (**Table – 1**). The mean age of the females in our study was 36.7 + 15.1 years and for the males, it was 40.5 + 19.4 years. This suggested that in the economically productive years of life, Pott's spine was more prevalent in females. The lower thoracic and the upper lumbar levels were found to be most commonly affected in most of the studies [1, 2, 8, 10]. In our study, the lumbar vertebrae were most commonly affected, followed by the dorsal vertebrae, which was similar to the findings of Sinan, et al. [8]. The atypical patterns of the tuberculous involvement of the spine consisted of the infection of a single vertebra or of multiple nonadjacent vertebrae (skip lesions), which in our study were noted in 1.42% and 2.85% of the cases respectively. Stark, et al. [1], suggested the presence of skip lesions in 4% of the cases, while in his study, Jain [11] suggested that multiple level tubercular lesions in the spine were observed in 16.3-71.4% of the cases when an MRI study of the whole spine was performed. We found skip lesions only in 2.85% of the cases. This could be because, for screening the whole spine, we had used a T2W sequence which was relatively less sensitive for detecting the minimal marrow edema in comparison to the STIR and the T1W sequences. Osborn [7] stated that a paraspinal abscess was present in 55-95% of the cases, which in our study was noted in 98.5% of the cases. Sinan, et al. [8] in their study, found the involvement of the inter vertebral disc in 72% of the cases, while we found it in 92.8% of the cases. Gibbus, which occurs predominantly in the dorsal spine, was observed in 27.2% of the cases, which was reported only in one third of the cases in a study which was done in Africa [10]. Gibbus, which occurs late in the course of the illness in a large number of patients, is caused due to the late referral poor health care system in the rural set up of India, as in Africa. An epidural involvement was observed in over 80% of the cases [11], which was similar to the finding in

our study (82.9%). Mirsaeidi, et al. [9] found the psoas abscess in 14.3% of the cases, while it was noted in 37.1% of the cases in our study. Contrast enhanced MRI with the use of Gadolinium chelates, improves the delineation of the abscesses which appear as an enhancing periphery and a necrotic core [3]. A smooth enhancement of the wall and a discrete paraspinal enhancement suggests a tubercular infection, with the thick irregular enhancement being generally due to pyogenic infections. An enhancement along the nerve roots is suggestive of early arachnoiditis. In our study, we rarely did contrast enhanced MRI, as it significantly increases the cost and moreover, the information which is obtained does not significantly alter the management. Sequential MRI scans can suggest the response to the treatment of Pott's spine. The appearance of sclerosis and the fatty changes in the bony tissue, the appearance of ankylosis, a reduction in the quantity of the epidural collection and the fibrosis and the resolution of the paraspinal signal changes highly favor a good response to the treatment. An increase in the quantity of the necrotic collection, an increase in the destructive process in the involved vertebrae with collapse and the appearance of a pathological process in a previously uninvolved vertebra suggests drug resistant tuberculosis and it warrants an alteration in the management protocol.

The cases which were included in this study were positive for tuberculosis on Ziehl Neelsen's staining or on the culture of the aspirates which were obtained from the pathological tissues. However, in few cases of tuberculosis, these investigations were negative and so, some cases of tuberculosis of the spine were excluded from this study.

Conclusion

MRI is the most valuable method for detecting the early disease and it is the preferred technique for defining the activity and the extent of the infection. It can also act as a guide to the surgical treatment in cases of tuberculosis of the spine.

The occurrence of various pathological lesions follow a characteristic pattern and they are likely to change with the variations in the predisposing factors for tuberculosis, like the prevalence of the HIV infection in the society, the nutritional status, etc. Hence, they should be monitored from time to time.

References

1. Stark DD, Bradley WG. Magnetic Resonance Imaging. 3rd edition. Mosby;. Chapter 86, Thoracic spine, 1999; p. 1851-82.
2. Burrill J, Williams CJ, Bain G, Conder G, Hine AL, Misra RR. Tuberculosis: A Radiologic Review. Radiographics, 2007; 27(5): 1255-73.
3. De Backer AI, Mortelé KJ, Vanschoubroeck IJ, Deeren D, Vanhoenacker FM, et al. Tuberculosis of the spine: CT and MR imaging features. JBR-BTR [Internet]. 2005 [cited 20 Feb 2012]; 88(2): 92-97.
4. Garg RK. Tuberculosis of the central nervous system. Postgrad Med J [Internet], 1999 [cited 20 Feb 2012]; 75: 133-140.
5. Bajwa GR. Evaluation of the role of MRI in spinal Tuberculosis: A study of 60 cases. Pak J Med Sci., [Internet]. 2009 [cited 20 Feb 2012]; 25(6): 944-947.
6. Kalita J, Misra UK, Mandal SK, Srivastava M. Prognosis of conservatively treated patients with Pott's paraplegia: logistic regression analysis. J Neurol Neurosurg Psychiatry [Internet], 2005 [cited 28 Apr 2012]; 76: 866-68.
7. Osborn AG. Diagnostic Neuroradiology. 1st edition, Elsevier; Chapter 20, Nonneoplastic disorders of the spine and spinal cord, 2009; p. 820-75.
8. Sinan T, Al-Khawari H, Ismail M, Ben-Nakhi A, Sheikh M. Spinal Tuberculosis: CT and MRI features. Ann Saudi Med

- [Internet], 2004 [Cited 20 May2012]; 24(6): 437-41.
9. Mirsaeidi SM, Tabarsi P, Amiri MV, Mansoori SD, Bakhshayesh- Karam M, Masjedi MR, et al. Clinical and Radiological Presentation of Adult Tuberculous Spondylitis. Tanaffos [Internet], 2003 [cited 29 Apr 2012]; 2(6): 59-65.
 10. Owolabi LF, Nagoda MM, Samaila AA, Aliyu I. Spinal tuberculosis in adults: A study of 87 cases in Northwestern Nigeria. Neurology Asia [Internet], 2010 [cited 20 Feb 2012]; 15(3): 239-44.
 11. Jain AK. Tuberculosis of the spine: A fresh look at an old disease. J Bone Joint Surg Br., July 2010; 92-B(70): 905-13.