

MORPHOMETRY AND MORPHOLOGY OF GLENOID CAVITY OF SCAPULA

Hetal Vaishnani ¹, Kinjal Jethva ^{*2}, Ashish Rathwa ³, Priyanka Sharma ⁴.

¹ Associate professor, Department of Anatomy, SBKS Medical College, Sumandeep vidyapeeth Pipariya, Vadodara, Gujarat, India.

^{*2} Assistant professor, Department of Anatomy, SBKS Medical College, Sumandeep vidyapeeth Pipariya, Vadodara Gujarat, India.

³ Tutor, Department of Anatomy, PDU Govt Medical college, RAJKOT, GUJARAT, India.

⁴ Tutor, Department of Anatomy, SBKS Medical College, Sumandeep vidyapeeth Pipariya, Vadodara, Gujarat, India.

ABSTRACT

Introduction: The Glenoid cavity is regarded as the head of the scapula. The morphology of glenoid cavity is highly variable. It articulates with the head of the humerus at the glenohumeral joint. Shape and dimensions of the glenoid cavity are important in the design and fitting of glenoid components for total shoulder arthroplasty. An understanding of variations in normal anatomy of the glenoid is essential while evaluating pathological conditions like osseous bankart lesions and osteochondral defects. The aim of the present study was to obtain the anthropometric data of the glenoid cavity of the scapula and to study the various shapes of the glenoid cavity which will help in management of shoulder pathology.

Materials and Methods: This study was done on 74 dry, unpaired adult human scapulae (36 right side and 38 left side) of unknown sex belonging to the saurashtra population. Maximum superior-inferior diameter and Maximum anterior-posterior diameter of the glenoid cavity were measured and. The shape of the glenoid cavity was classified as inverted comma shaped, pear shaped and oval shaped depending upon the presence or absence of a notch on the glenoid rim.



Results: The average SI diameter on right and the left sides were 38.49 ± 3.17 mm and 38.06 ± 3.34 mm respectively. The average AP-1 diameter of the right glenoid were 24.76 ± 2.49 mm and that of the left was 24.23 ± 2.14 mm. The mean AP-2 diameter of the right glenoid was 18.83 ± 2.19 mm and that of the left was 17.97 ± 2.08 .

Conclusion: These findings suggest that the difference in size of the glenoid cavity in Gujarati population may have to be taken into consideration while deciding the size of the glenoid component in shoulder arthroplasty in this population.

KEY WORDS: Scapula, Glenoid cavity, Glenoid notch, Glenohumeral joint.

Address for Correspondence: Dr.Kinjal Jethva, Assistant professor, Department of Anatomy, SBKS Medical College, Sumandeep vidyapeeth Pipariya, Vadodara Gujarat, India.

E-Mail: kvj70827@gmail.com

Access this Article online	Journal Information
Quick Response code  DOI: 10.16965/ijar.2017.467	International Journal of Anatomy and Research ICV for 2016 90.30 ISSN (E) 2321-4287 ISSN (P) 2321-8967 https://www.ijmhr.org/ijar.htm DOI-Prefix: https://dx.doi.org/10.16965/ijar 
	Article Information
	Received: 05 Oct 2017 Peer Review: 06 Oct 2017 Revised: None
	Accepted: 18 Nov 2017 Published (O): 05 Jan 2018 Published (P): 05 Jan 2018

INTRODUCTION

The scapula is a large, flat, triangular bone which lies on the posterolateral aspect of the chest

wall, covering parts of second to seventh ribs. Its lateral angle, truncated and broad, bears the glenoid cavity which articulates with the head

of the humerus at the glenohumeral joint and may be regarded as the head of the scapula[1]. Glenoid cavity surface is covered with hyaline cartilage in the fresh state and its slightly raised margins give attachment to a fibrocartilaginous structure the glenoid labrum which deepens the cavity [2]. Due to presence of this glenoid notch, various shapes of glenoid cavity are found like pear-shaped, oval or inverted comma shaped [3,4].

The glenohumeral joint is most unstable joint in the body due to its performance of a wide range of movements. Dynamic factors of the rotator cuff muscles and the static factors of the glenohumeral ligaments, the labrum and the joint capsule play a role in glenohumeral joint stability [5].

The shoulder joint is the most frequently dislocated joint in the body. Dislocations with fractures of the glenoid are also quite common in trauma [6]. For the management of this, prostheses and arthroplasty are required a number of times. The anatomical basis and variations of shape and size of glenoid cavity of scapula is of fundamental importance in understanding of rotator cuff disease, shoulder dislocation and to decide the proper size of the glenoid component in the shoulder arthroplasty.

AIM: The aim of the current study was to measure the various diameter of glenoid cavity of the scapula and to study the various shapes of the glenoid cavity for better understanding and management of shoulder pathology.

MATERIALS AND METHODS

The cross sectional study was performed in Department of Anatomy in PDU Govt. Medical College Rajkot, Gujarat. A total of 74 dry scapula (36 right side and 38 left side) bones were studied from teaching collection of the Anatomy department. The bones belonged to mature specimens but the exact ages and gender of the specimens were not known. All the scapula selected were dry, complete and showed normal anatomical features and bones showing pathology were excluded from study. All measurement was carried out by the same instrument. The data were then entered and analysed using the Microsoft Excel 2010.

The following parameters of the glenoid cavity were studied. The first three diameters were measured as per the study of Mamatha et al [6]. All the measurements were taken manually with the help of a digital vernier caliper and recorded in millimeters.

Superior-Inferior Glenoid Diameter (SI): Represents the maximum distance from the inferior point on the glenoid margin to the most prominent point of the supraglenoid tubercle, which is also the maximum height of the glenoid cavity(fig -1)

Anterior-Posterior Glenoid Diameter (AP-1): Represents the maximum breadth of the articular margin of the glenoid cavity perpendicular to the glenoid cavity height .(fig-2)

Anterior-Posterior Glenoid Diameter (AP-2): Represents the anterior-posterior diameter at the peak of the glenoid notch.(fig-3)

Shape of the Glenoid Cavity: Shape made by the slightly raised rim of the glenoid cavity. (fig-4,5,6)

Fig. 1: Showing measurements of SI diameter of glenoid cavity of scapula.

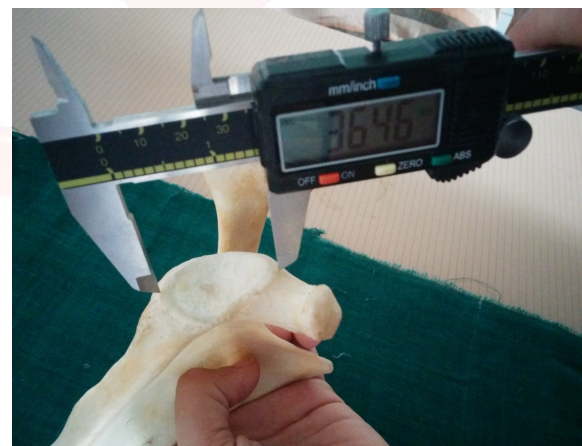

Fig. 2: Showing measurements of AP1 diameter of glenoid cavity of scapula.



Fig. 3: Showing measurement of AP 2 diameter of glenoid cavity of scapula.



Fig. 4: Showing oval shaped glenoid cavity.

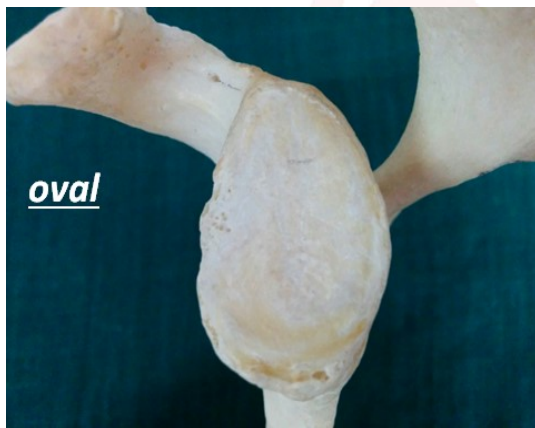

Fig. 5: Showing inverted comma shaped glenoid cavity.

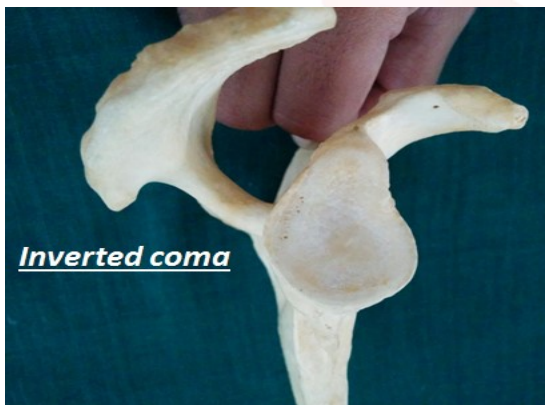
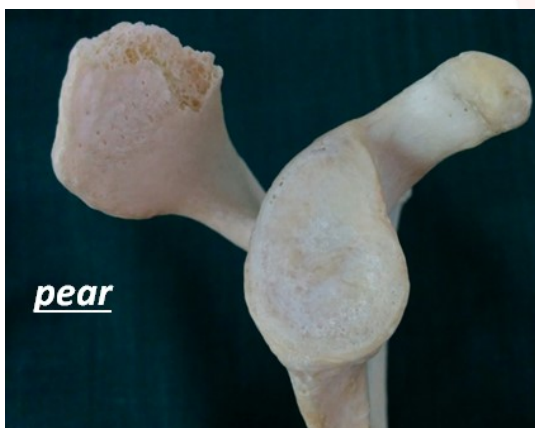
Fig. 6: Showing inverted comma shaped glenoid cavity



RESULTS

Table 1: Comparison of various measurements of right and left glenoid cavity.

Parameter	Range (mm)		Mean (mm)		Standard Deviation (mm)		P Value
	Right	Left	Right	Left	Right	Left	
SI Diameter	32.8-44.77	32.07-44.55	38.49	38.06	±3.17	±3.34	0.536
AP 1 Diameter	20.0-29.47	20.4-28.13	24.76	24.23	±2.49	±2.14	0.45
AP 2 Diameter	14.27-23.39	13.95-22.07	18.83	17.97	±2.19	±2.08	0.236

The data were obtained in 36 scapulae of the right side and 38 scapulae of the left side. In present study SI glenoid diameter of the right side varied from 32.8 mm to 44.77mm with an average of 38.49 ± 3.17 mm and left side varied from 32.07mm to 44.05 mm, with an average of 38.06 ± 3.34 mm. (table -1)

The AP-1 glenoid diameter of the right side varied from 20.0mm to 29.47mm, with an average of 24.76 ± 2.49 mm. The AP-1 glenoid diameter of the left side varied from 20.4mm to 28.13mm, with an average of 24.23 ± 2.14 mm.(table-1)

The AP-2 glenoid diameter of the right side varied from 14.27 mm to 23.39 mm with an average of 18.83 ± 2.19 mm . The AP-2 glenoid diameter of the left side varied from 13.95 mm to 22.07mm with an average of 17.97 ± 2.08 mm. (table-1)

Table 2: Comparison of shape of right and left glenoid cavity.

Shape	Incidence of shape	
	Right (n)	Left (n)
Oval	38.89%(14)	34.21%(13)
Pear	44.44%(16)	47.37%(18)
Inverted Coma	16.67%(6)	18.42%(7)

A total of 36 glenoid cavities on right side were measured. Out of them 6 were of inverted comma shaped, 16 were found to be pear shaped and 14 were of oval shaped. On the right side incidence of inverted comma shaped, pear shaped and oval shaped were 16.67%, 44.44% and 38.89% respectively. Total of 38 glenoid cavities were measured on the left side. Out of them 7 were of inverted comma shaped, 18 were of pear shaped and 13 were of oval shaped. On the left side incidence of inverted comma shaped, pear shaped, oval shaped were 18.42%, 47.37% and 34.21% respectively.(table -2)

DISCUSSION

Table 3: Comparison of SI and AP diameter of present study with previous studies.

Observers	No. of Specimens	Mean SI Diameter (mm)	Mean AP1 Diameter (mm)
Iannotti et al. (1992) [8]	140	39 ± 3.5	29 ± 3.
Von Schroeder et al (2001) [9]	30	36±4	28.6±3.3
Churchill et al (2001) [4]	Male-200	37.5±2.2	27.8±1.6
	Female-144	32.6±1.8	23.6±1.5
Luis Rios Frutos et al (2002) [10]	Male-65	36.08±2.0	26.31±1.5
	Female-38	31.17±1.7	22.31±1.4
Ozer et al (2006) [11]	Male-94	38.71±2.71	27.33±2.4
	Female-92	33.79±3.08	22.72±1.72
Coskun et al (2006) [16]	90	36.3 ± 3	24.6 ± 2.5
Karelse et al (2007) [12]	40	35.9±3.6	27.2±3
Mamatha T et al (2011) [6]	Right-98	33.67±2.82	23.35±2.04
	Left-104	33.92±2.87	23.02±2.30
Rajput et al (2012) [13]	Right-43	34.76±3	23.31±3.0
	Left-57	34.43±3.21	22.92±2.80
Kavita et al (2013) [14]	Right-67	35.2±3.0	25.0±2.7
	Left-62	34.7±2.8	24.9±2.4
Dhindsa GS et al (2014) [15]	Right-41	34.13±3.16	24.05±2.86
	Left-39	34.11±2.57	23.36±2.22
Patil et al (2014) [17]	Right:104	33.68±4.32	23.29±2.34
	Left: 120	32.09±4.11	24.90±2.95
Present study (2015)	Right-36	38.49±3.17	24.75±2.49
	Left-38	38.06±3.34	24.23±2.14

The present study was performed on dry human scapulae. The comparison of data between present study and previous studies found several differences as well as similarities in the dimensions of the scapula and glenoid cavity (Table 3).

In the present study the average superior-inferior diameter of the right glenoid was 38.49±3.17mm and the average superior-inferior diameter of the left glenoid was 38.06±3.34 mm.

Von Schroeder et al [9], Coskun et al [16] and Karelse et al [12] reported the SI diameter to be 36±4mm, 36.3±3 mm and 35.9±3.6 mm respectively. All these values are lower than what was recorded in our study.

Mamatha et al [6], Rajput et al [13] and Kavita et al [14], Patil et al [17] measured the SI diameter of right and left side separately. The mean SI diameter of right side measured by these three authors was 33.67 ± 2.82mm, 34.76±3 mm and 35.2±3.0 mm, 33.68±4.32 respectively and of the left side was 33.92 ± 2.87 mm, 34.43±3.21mm 34.7±2.8 mm, 32.09±4.11 mm respectively. Churchill et al [4], Frutos LR [10], Ozer et al [11] measured the SI diameter of the male and female glenoid separately. The average SI

diameter of male glenoid measured by these authors was 37.5±2.2, 36.08±2.05 mm and 38.71±2.71mm respectively. All these measurements are near to that reported in our present study. In our study the sex of the scapulae was not known, therefore we could not measure them separately.

In the present study the average AP1 diameter of glenoid cavity on the right side was 24.76±2.49mm and on left side was 24.23±2.14mm. The combined average of both sides was 24.54 ± 2.32mm.

This was very higher to what was observed in the female glenoids studied by Churchill et al [4], Luis Rios Frutos [10] who have recorded the average AP-1 diameter to be 23.6 ± 1.5mm, 22.31 ± 1.49mm. respectively. The values recorded for the AP-1 diameter for the male glenoids were 27.8 ± 1.6mm by Churchill et al [4] and 26.31 ± 1.57mm by Luis Rios Frutos [10]. All these values were very close to our combined average of both right and left sides, 24.54 ± 2.32mm

Table 4: Comparison of AP2 diameter of present study with previous studies.

Observers	No of specimens	Mean AP2 Diameter
Iannotti et al 1992 [8]	140	23±2.7mm
Mamatha et al 2011 [6]	Right-98	16.27±2.01mm
	Left-107	15.77±1.96mm
Patil et al 2014 [17]	Right -104	15.74±1.75mm
	Left -120	16.81±1.74mm
Present study	Right-36	18.83±2.19mm
	Left-38	17.97±2.08mm

In the present study the average AP2 diameter of glenoid cavity on the right side was 18.83±2.19mm and on left side was 17.97±2.08mm. The combined average of both sides was 18.4 ± 3.23mm. This was much lower than what was observed by Iannotti et al [8], which was 23 ± 2.7mm. Average AP2 diameter of present study found very close to what observed in study by Patil et al [17], which were 15.74±1.75mm on right side and 16.81±1.74 on left side. Mamatha et al [6] recorded the average AP-2 diameter of upper half of the right glenoid was 16.27±2.01mm and that of the left glenoid was 15.77±1.96mm with combined average of 16.02±2.0mm. (Table-4) these values are near to present study.

In the present study, 38.89 % oval, 44.44% pear, 16.67% inverted comma shaped glenoid cavity found on right scapula. 34.21% oval, 47.37% pear, 18.42% inverted comma shaped glenoid cavity found on left scapula.

The percentage of glenoids with both indistinct and distinct notch was 61.11% on the right side and 65.79% on the left side. Mamatha et al[6] had found it to be 80% on the right side and 76% on the left side. Prescher and Klumpen[3] had observed it to be 55% which was lesser than in the current study. In the current study, oval glenoids comprised only of 38.89% on the right side and 34.21% on the left side. As compared to Mamatha et al[6] who found it to be 20% on the right side and 24% on the left side. Prescher and Kulmpen [3]observed that 45% of the glenoids were oval shaped. Coskun N et al[16] studied 90 scapulae and found that, in 72% of the specimens, the glenoid notches of the scapulae was absent or oval shaped, whereas in 28% the notch was well expressed and the glenoid cavity was pear shaped. These findings were higher than that of the current findings.

CONCLUSION

The difference seen between the values of present study and that of other workers could be explained on the basis of ethnic and racial variations. Thus knowledge of the variation in the shape and dimensions of the glenoid are important in better understanding of the shoulder pathology and in designing and fitting of glenoid components for total shoulder arthroplasty. Since the current study was performed on a limited number of scapulae, further cadaveric, radiological and clinical studies are indicated.

ABBREVIATIONS

SI- Superior inferior

AP1- Anterior posterior1

AP2- Anterior posterior2

mm- millimeter

n- number of bones

Conflicts of Interests: None

REFERENCES

- [1]. Johnson D. Pectoral Girdle, Shoulder region and Axilla. In: Standring S, Borley NR, Collins P, Crossman AR, Gatzoulis MA, Healy JC, et al, editors. Gray's

- Anatomy, The Anatomical Basis of Clinical Practice. 40th ed. Churchill Livingstone; 2013. p. 791-822.
- [2]. Richard L, M Newell, 2005; Gray's anatomy. The anatomical basis of clinical practice. Thirty-nine edition. Churchill livingstone (London): Harcourt publications. pp 819-822.
- [3]. Prescher A, Klumpen T. The glenoid notch and its relation to the shape of the glenoid cavity of the scapula. J Anat 1997; 190(3): 457-60.
- [4]. Churchill RS, Brems JJ, Kotschi H. Glenoid size, inclination, and version: An anatomic study. J Shoulder Elbow Surg 2001; 10(4): 327-32.
- [5]. Ly JQ, Beall DP, Sanders TG. MR imaging of glenohumeral instability. AJR Am J Roentgenol 2003;181:203-13.
- [6]. Mamatha T, Pai S R, Murlimanju BV, Kalthur SG, Pai MM, Kumar B. Morphometry of glenoid cavity. Online J Health Allied Scs. 2011; 10(3):7.
- [7]. Mallon WJ, et al, 1992; Radiographic and geometric anatomy of the scapula. Clinical orthopedics 277: 142-154.
- [8]. Iannotti JP, Gabriel JP, Schneck SL, Evans BG, Misra S. The normal glenohumeral relationships. An anatomical study of one hundred and forty shoulders. J Bone Joint Surg Am 1992;74:491-500.
- [9]. Von Schroeder HP, Kuiper SD, Botte MJ. Osseous anatomy of the scapula. Clinical orthopedics and related research, 2001;383:131-139.
- [10]. Frutos LR. Determination of sex from the clavicle and scapula in a Guatemalan contemporary rural indigenous population. Am J Forensic Med and Pathol. 2002;23:284-8.
- [11]. Ozer I, Katayama K, Sagir M, Gulec E. Sex determination using the scapulae in medieval skeletons from east Anatolia. Coll Anthropol 2006; 30:415-419.
- [12]. Karelse A, Kegels L, De Wilde L. The pillars of the scapula. Clin Anat 2007;20:392-9.
- [13]. Rajput HB, Vyas KK, Shroff BD. A Study of Morphological Patterns of Glenoid Cavity of Scapula. Natl J Med Res 2012;2(4):504-7.
- [14]. Kavita P, Singh J, Geeta. Morphology of Coracoid process and Glenoid cavity in adult human Scapulae. International Journal of Analytical, Pharmaceutical and Biomedical Sciences 2013; 2(2): 19-22.
- [15]. Dhindsa GS, Singh Z. A study of morphology of glenoid cavity. Journal of Evolution of Medical and Dental Sciences. 2014;3:7036-43.
- [16]. Coskun N, Karaali K, Cevikol C, Demirel BM, Sindel M. Anatomical basics and variations of the scapula in Turkish adults. Saudi Med J 2006;27(9):1320-5.
- [17]. Patil GV, Kolagi SI, Ramdurg U. Morphometrical study of scapular glenoid cavities. Global Journal of Medical Research: Orthopedics and Musculoskeletal system. 2014;14(2):9-14.

How to cite this article: Hetal Vaishnani, Kinjal Jethva, Ashish Rathwa, Priyanka Sharma. MORPHOMETRY AND MORPHOLOGY OF GLENOID CAVITY OF SCAPULA. Int J Anat Res 2018;6(1.1):4798-4802. DOI: 10.16965/ijar.2017.467