



REDUCTION IN RATE AND SEVERITY OF ANASTOMOTIC LEAKAGE IN CASE OF COLORECTAL ANASTOMOSIS WITH TRANSANAL TUBE PLACEMENT WITHOUT DOING DIVERTING ILEOSTOMY.

General Surgery

**DR MAHESH M
PUKAR**

PROFESSOR IN SURGERY, SBKSMI & RC, PIPARIA, VADODARA

**DR ZIL PARAG
DESAI**

RESIDENT IN SURGERY, SBKSMI & RC, PIPARIA, VADODARA

ABSTRACT

Background: Diverting ileostomies are mostly done following colorectal anastomosis to prevent the septic sequelae of Anastomotic leakage.

Introduction: One of the major complications of colorectal anastomosis is anastomotic leakage⁽¹⁾. Ileostomy is used as to decrease the intra-luminal pressure of intestine henceforth preventing the leakage. But diverting ileostomies has its own complications and patient's compliance is not very good.

Material and methods: This is a single centre retrospective study which was conducted between February 2015 to December 2016 which shows the importance of transanal tube placement in colorectal anastomosis after excision of benign or malignant tumors.

Discussion: Chun-soek yang MD et.al, has underwent a study by comparing between two groups one with transanal tube placements and the other group without it in the jan, 2016 and it showed that the overall leakage rate was 10.8% without any significant difference between transanal tube placements (9.8%) and without placing transanal tube was 11.8%⁽²⁾. In present study, leakage is not found in overall 6 patients.

Results: So just by placing transanal tubes, the chances of leakage from colorectal anastomotic site can be reduced and complications of the ileostomy can be prevented and thereby reducing the morbidity and hospital stay.

Conclusion: This study concludes that, the diverting ileostomies are not always necessary and should be used selectively.

KEYWORDS:

Tranrectal tube, Anastomosis, Leak

Introduction:

One of the major complication following colorectal anastomosis is Anastomotic leakage⁽¹⁾. Placement of transanal tube reduces the endoluminal pressure and gives diversion to the fecal contents helping in the healing of the anastomosis. Several factors such as anatomic inaccessibility, low blood supply, tightly low anal sphincter below an ultralow anastomosis and pelvic hematoma contribute to the increased chances of complications. This transanal tube placement has proved its role in preventing Anastomotic failure, avoidance of second surgery and lower morbidity. Many randomized control studies have been done which shows that protective loop ileostomy and transanal tube placement reduces the complications. But still by doing ileostomy there are many complications related to it like like dehydration, nutrition deficiencies, rectal discharge, parastomal hernias, maceration of the surrounding skin, stomal stricture, stoma prolapsed, stomal retraction, prolapsed; phantom rectum in which patient feel like they need to pass stools even though they don't have a working rectum; proctitis include diarrhea, abdominal pains, cramps and high temperature⁽⁴⁾⁽⁵⁾. Hence this is a retrospective study which concludes that patients having colorectal anastomosis heals well without any complications by placement of transanal tube and by avoiding diverting ileostomy.

Aim and Objectives:

To review the outcome of the colorectal anastomosis after transanal tube placement and by avoiding diverting ileostomies.

To study the complications and the benefits of transanal tube placement in anastomosis healing.

Material and Methods:

This study has been conducted between February 2015 to December 2016 at Dhiraj General Hospital, Sumandeep Vidyapeeth, Pipariya, and Vadodara. The patients included in this study were those who underwent colorectal anastomosis for conditions like colorectal mass, sigmoid volvulus, recto-sigmoid perforation with transanal tube placement.

Those patients not willing for the study and having immuno-compromised status were excluded from this study.

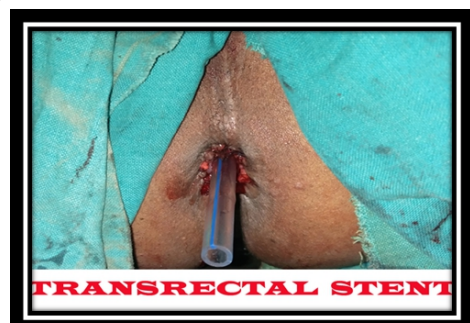
Patients coming to the out-patient department and emergency department who necessitated the excision of colorectal pathology were examined and pre-operative workup such as complete hemogram, blood sugar, renal and liver function tests, coagulation studies, serology, Chest x-ray and Echocardiogram were done. Following that, investigations necessary for confirmation of diagnosis like X-ray abdomen standing, Ultrasonography and Contrast Enhanced Ct scan were done.

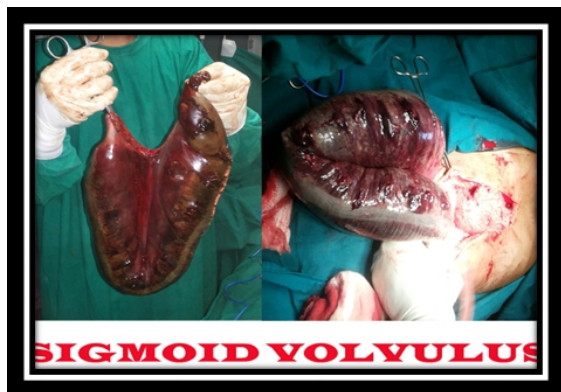Preanaesthetic checkup was done for all patients.

Procedure:

General anesthesia was given to all the patients. In the supine position, after painting and draping, midline incision was given. The pathology was identified in between colon and rectum. Following this resection and anastomosis was done in two layers with Vicryl 3-0 and Silk 3-0 between the two ends. After that transanal tube was placed beyond the anastomosis per rectally. Abdominal drain, no. 30 was kept in the pelvis. Abdomen was closed in layers.

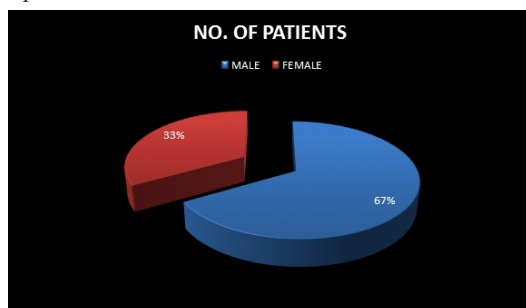
Patients were mobilized on post-operative day 1. Ryle's tube no.14 was kept in situ till the bowel sounds were heard. Transanal tube was removed on post-operative day 8. Drain output in terms on quantity, color and content was monitored. Drain was removed on post-operative day 7-9 after the patients were on full diet and had passed stools.





Results:

Six patients met the inclusion criteria and retrospective study was done which showed the importance of Transanal tube placement. Proper follow up was made of all these patients and none had anastomotic leakage during the course of hospital stay or after that. One out of 6 patients has developed cardio-pulmonary complications on his post operative day 35 and he died. Hence by avoiding diverting ileostomy, its complications such as long hospital stay, ileostomy closure can be reduced. Hence overall morbidity in such patients has been decreased.



Discussion:

The main aim of this study is to reduce the post-operative complications of colorectal anastomosis. Anastomotic leakage is the most common complication. Indicators of anastomotic leakage include the occurrence of clinical symptoms such as fever, discharge of feces, pus or gas from the abdominal drain, and the occurrence of peritonitis within 30 days after surgery. Although trans-anal tube placement and diverting ileostomy was done following colorectal anastomosis but their role remained unclear and the post operative complications of ileostomy as well as patients compliance made this operation very unpopular^[6]. Mostly the aim was to reduce the anastomotic leakage which is the commonest complication; by placing the transanal tube hence it reduces the intraluminal pressure without the need of doing diverting ileostomy^[7]. Most anastomotic leakages occur within 7 days after surgery, early removal of the transanal tube may lead to anastomotic dehiscence. It shows that diverting ileostomies should be avoided and can be used selectively. Chun-soek yang MD et.al, has underwent a study by comparing between two groups one with transanal tube placements and the other group without it in the jan,2016 and it showed that the overall leakage rate was 10.8% without any significant difference between transanal tube placements(9.8%) and without placing transanal tube was 11.8%^[2]. A clinically significant leakage was diagnosed in 25 patients (13%)^[3]. The analysis showed no significant protective effect of the transanal tube, and is statistically insignificant. On this basis it was decided to discontinue the study prematurely for ethical reasons.

This study includes 6 patients with colorectal anastomosis in different colorectal pathologies but did not show anastomotic leakage. This study has its limitations in terms of sample size.

Conclusion:

Transanal tube placements, hence decreases and prevents the chances of anastomotic leakage. Diverting ileostomies and its complications can be avoided by just placing the transanal tubes following colorectal anastomosis.

References:

1. Debra-L, Richardson, Andrea mariani, A. Cliby; Risk factors for anastomotic leakage after resection of recto-sigmoid mass for ovarian cancers; gynaecologic oncology 103(2006) 667-672
2. Rectal tube drainage reduces major anastomotic leakage after minimally invasive rectal cancer surgery Chun-Seok Yang, M.D., 2016; 123
3. Transanal stent in anterior resection does not prevent anastomotic leakage S. Bu "low", O. Bulut*, I. J. Christensen*, H. Harling† and The Rectal Stent Study Group 1 *Department of Surgical Gastroenterology, 2006 Blackwell Publishing Ltd. Colorectal Disease, 8, 494–496
4. Matthiessen P, Hallbook O, Rutegard J, Simert G, Sjodahl R. Defunctioning stoma reduces symptomatic anastomotic leakage after low anterior resection of the rectum for cancer: a randomized multicenter trial. Ann Surg 2007; 246: 207-14.
5. Peng J, Lu J, Xu Y, et al. Standardized pelvic drainage of anastomotic leaks following anterior resection without diversionary stomas. Am J Surg 2010; 199: 753-8.
6. Cong ZJ, Fu CG, Wang HT, Liu LJ, Zhang W, Wang H. Influencing factors of symptomatic anastomotic leakage after anterior resection of the rectum for cancer. World J Surg 2009; 33: 1292-7.
7. Zhao WT, Hu FL, Li YY, Li HJ, Luo WM, Sun F. Use of a transanal drainage tube for prevention of anastomotic leakage and bleeding after anterior resection for rectal cancer. World J Surg 2013; 37: 227-32