

Assessment of Appropriateness of MRI Study in Evaluation of Lumbar Spine in Adult Patients - A Retrospective Study.

Rajeshkumar Rathore¹, Kalpeshkumar K. Patel²

¹Associate Professor, Department of Radiology, ²Associate Professor, Department of Radiology, Dhiraj Hospital, SBKS Medical College, Sumandeep Vidhyapeeth, Pipariya, Vadodara, India

Corresponding author: Dr Kalpeshkumar K. Patel, Associate Professor, Department of Radiology, Dhiraj Hospital, SBKS Medical College, Sumandeep Vidhyapeeth, Pipariya, Vadodara, India

DOI: <http://dx.doi.org/10.21276/ijcmsr.2019.4.2.36>

How to cite this article: Rajeshkumar Rathore, Kalpeshkumar K. Patel. Assessment of appropriateness of MRI study in evaluation of lumbar spine in adult patients - A retrospective study. International Journal of Contemporary Medicine Surgery and Radiology. 2019;4(2):B166-B169.

ABSTRACT

Introduction: Degenerative disease of the lumbar spine is a common condition that radiologists encounter on a daily basis. The diagnostic imaging and clinical interventions for back pain are costly which adds considerable burden on health care systems. MRI plays an important role in the assessment of low back pain and lumbar spine. A radiologic report holds lesser value, if previous history and clinical evaluation are not suggestive of a pathology. Hence, the aim of the present study was to investigate the appropriateness of MRI usage of lumbar spine among adult patients.

Material and Methods: This retrospective study in which all the cases of lumbar spine MR imaging during the defined period were included. The demographic details included the patient's age, gender, chief complaints, followed by duration of symptoms and specialities of prescribing physician. All patients underwent lumbosacral spine MRI to be included in the study. The inclusion criterion was lumbar back pain experienced in standing position whereas the patients with any previous spine surgery at any level and/or referred inability to maintain standing position for the scheduled examination time were excluded from this study.

Results: Lumbar disc bulging was the most common diagnosis, followed by scoliosis, kyphosis and infection. Chief complaints such as walk difficulties, back injury and referred leg pain were associated with greater chance of detecting potentially clinically positive lumbar MR image findings, as compared to simple back pain. Duration of back pain, leg pain, back and leg pain and walking difficulties were not found to be associated with greater rate of potentially clinically positive lumbar spine diagnosis.

Conclusion: Magnetic resonance imaging has proven to be an indispensable tool for the orthopaedic spine surgery than x-rays. The value in assessing normal lumbar anatomy, internal disc chemistry and architecture, features of lumbar spine degeneration, and in diagnosing herniated lumbar discs has been well documented. Thus, MRI is the best non-invasive approach which provides a clear 3D visualization of spinal structures for the detection of lumbar pathologies.

Keywords: Magnetic Resonance Imaging, Lumbar Spine, Orthopaedic Surgeon

INTRODUCTION

One of the most common causes of disability is the degenerative disease of the lumbosacral spine which is a complex biomechanical system adaptable to various kinds of stress generated by posture, daily activities, and traumatic events. The lumbar spine has five vertebrae (L1 to L5) which constitute the complex anatomy of the lumbar spine as they are linked to ligaments, tendon and muscles.¹

The muscles of lumbar spine are functional groups of muscles which are grouped as extensors, flexors, lateral flexors and rotators. Pain is mediated by nociceptors which are peripheral sensory neurons that alert us by transducing the stimuli. Central sensitization takes place in a variety of chronic pain disorders including low back pain, temporomandibular disorders, osteoarthritis, fibromyalgia etc. Low back pain is experienced very frequently by people at some point in their

lives. It has been estimated that of the 1-year incidence of a first-ever episode of low back pain range between 6.3 % and 15.4 %, whereas estimates of the 1-year incidence of any episode of low back pain range between 1.5 % and 36 %.^{2,3} The MRI of the lumbar spine can be useful in evaluating symptoms such as lower back pain, leg pain, numbness, tingling or weakness or problems with bladder and bowel control. It has also been found to diagnose tumors, bleeding, swelling; developmental abnormalities and infection in the vertebrae or surrounding tissues.⁴ The causes of low back pain are multifactorial which is affected by mechanical stress and genetics. The prevalence of pain is 70% to 85% as a result of which this problem is very common nowadays. It has been found from the previous literature that low back pain is the most common cause of disability among people aged 45 years or younger, with a financial burden of \$100 billion dollars per year.⁵

Back pain affects the population at one time or the other. Various complications can lead to missed or mismanaged spinal abnormalities with neurological problems. Such complications require proper medical treatment to avoid serious patient injury. Therefore, correct diagnosis helps in more effective and reduced costly methods of treatment. Approximately 10% of back pain is diagnosable, with current diagnostic technologies.⁶

Magnetic resonance imaging has been proven for a clear three-dimensional visualization of spinal structures, due to which it is considered to be the non-invasive approach for diagnosing the lumbar pathologies. Findings such as disc degeneration, disc herniation, spinal canal stenosis, facet joint hypertrophy are much commonly found with the help of MR images.⁷

The lumbar spine of MRI constitutes a sagittal T1-weighted spin echo sequence, a sagittal T2-weighted spin echo sequence, and axial T2-weighted images. There are additional sequences with axial T1-weighted sequences, sagittal fat-nulling T2-weighted sequences such as short tau inversion recovery (STIR) or modified Dixon (mDixon), and gadolinium-based contrast enhanced T1-weighted sequences can be obtained depending on the institution and the indication for the examination of MRI.⁸

At multiple levels, for the assessment of the degree of spinal stenosis, sagittal T2-weighted images provide excellent contrast between cerebrospinal fluid (CSF) in thecal sac and the surrounding structures on a single image. Such sequences help in the assessment of the intervertebral discs, and the presence of disc herniation. Despite the well-defined limitations MRI of lumbar spine is used for the screening of back pain.⁹ Therefore, the aim of the present study was to assess the appropriateness of MRI of lumbar spine among adult patients.

MATERIAL AND METHODS

The present study was a retrospective study in which 300 patients were included each with a history of low back pain. All patients underwent lumbosacral spine MRI and gave informed written consent before included in the study. Patients who experienced lumbar back pain in a standing position were taken in this study. Patients with history of previous spine surgery at any level and/or referred inability to maintain standing position for the scheduled examination time were excluded from this study.

The study was conducted in Dhiraj Hospital, SBKS medical college, Sumandeep vidhyapeeth, Pipariya, Vadodara on 1.5T Phillips MRI machine from December 2018 to April 2019. Demographic details such as patient's age, gender, chief complaints, duration of symptoms, specialties of prescribing physician, and MR images were taken for analyses. On the basis of potential clinical relevance, MR diagnosis was classified as potentially clinically positive or clinically negative. The diagnosis of MR of systematic lumbar spine diseases or neurologic compression which may need clinical interventions are defined as potentially clinically positive diagnosis, including lumbar disc herniation, lumbar spinal canal stenosis, spondylolisthesis, spinal tumour, spinal infection, fresh vertebral fracture, and spinal deformity

(scoliosis or kyphosis).¹⁰

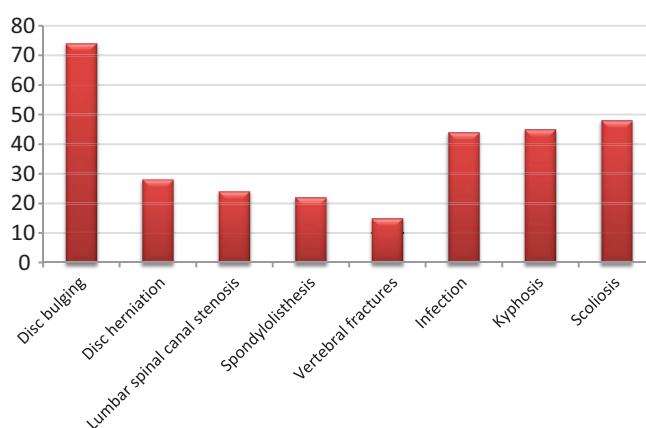
Findings which were common among both healthy individuals and back pain patients, which deserve little or no clinical attention, were classified as clinically negative diagnosis, with involvement of degeneration of disc, high intensity zone in the disc, obsolete vertebral fractures, deposition of fat in the vertebral body, degeneration of facet joint and cysts on the disc. If there are potentially clinically positive findings on MR images, study was regarded as appropriate otherwise it was considered to be inappropriate.

STATISTICAL ANALYSIS

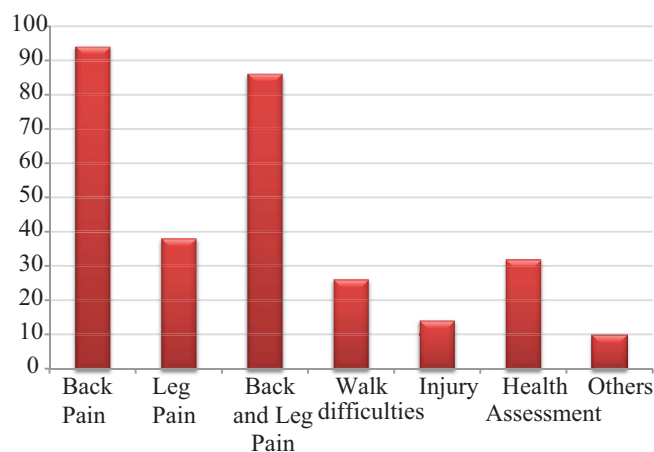
The data was entered into Microsoft excel sheet and the descriptive statistics was performed and was presented in the form of tables and graphs as percentage. A multiple variable regression analysis was used to explore the determinants for the rate of potentially clinically positive diagnosis.

RESULTS

In the present study, the Graph no. 1 shows that the most common finding evaluated by referring doctors among the 300 patients was disc bulging i.e. in 24.6% followed by scoliosis in 16% and kyphosis in 15%. About 14.6% of them complaint regarding infection followed by disc herniation in 9.3%, lumbar spinal canal stenosis in 8%, spondylolisthesis in 7.3% and vertebral fractures in 5% of the patients.



Graph-1: Shows the distribution of data based on diagnosis evaluated by referring doctor



Graph-2: Shows the distribution of data based on chief complaints for ordering a lumbar spine study

Patient's Age	N
20-30 years	25
31-40 years	28
41-50 years	82
51-60 years	88
61-70 years	54
>70 years	23
Patient's Gender	N
Female	176
Male	124
Prescribing Physician	N
Orthopaedic Surgeon	152
Neurologist and Neurosurgeon	48
Specialist of internal medicine	54
General practitioner	46

Table-1: Shows the distribution of data based on percentage related to age, gender and prescribing physician

Chief Complaint	Back Pain		Leg Pain		Back and Leg		Walking difficulties	
Duration	OR	P	OR	P	OR	P	OR	P
<1 month	1.00		1.00		1.00		1.00	
1-3 months	0.54	0.84	0.21	0.14	1.42	0.18	1.16	0.64
3-12 months	0.32	0.32	0.28	0.41	1.22	0.22	1.28	0.48
>12 months	0.44	0.08	0.46	0.09	0.88	0.07	0.82	0.59

Table no. 2 shows the associations between the MRI findings and presence of potentially clinically positive MR findings with duration of chief complaints, adjusting for age and gender

It was found that the most common chief complaint was found to be back pain among 31.3% of the patients followed by back and leg pain both in 28.6% of the patients. Leg pain was found in 12.6% followed by walk difficulties among 8.6% and injury in 4.6% of the patients. Health assessment and other chief complaint were found to be 10.6% and 3.3% respectively (graph-2).

Females (58.6%) were more than males (41.3%) in the present study and the most involved age group was 51-60 years (29.3%), 41-50 years (27.3%) and 61-70 years (18%). The least age group was more than 70 years (7.6%) and 20-30 years (8.3%). The most common prescribing physician was orthopaedic surgeons (50.6%) followed by specialist of internal medicine (16%) and neurologists and neurosurgeon (18%) with general practitioner (15.3%). (table-1).

In Table no. 2, it is observed that the duration of back pain, leg pain, back and leg pain and walking difficulties were not found to be associated with greater rate of potentially clinically positive lumbar spine diagnosis when adjusted for age and gender.

DISCUSSION

In the present study, MRI is the imaging modality of choice for evaluation of the lumbar spine in patients with suspected lumbar disc bulging and herniation. It allows radiologists to diagnose disease early before bone destruction becomes visible on radiographs or even CT. This is because MRI shows the extent of the disease and soft-tissue involvement, especially epidural extent, it is considered critical before surgical intervention. Contrast-enhanced MRI improves detection of intravertebral, paravertebral, and epidural abscesses by enhancing the margin of the abscess, whereas

the central portion of abscess remains unenhanced.^{11,12}

MRI is considered the best approach for the workup of spinal stenosis. The reported sensitivity and specificity of MRI for the diagnosis of spinal stenosis varies from 77% to 90% and 72% to 100%, respectively, with the reference standard in these studies consisting of either surgical findings or adequate clinical follow-up. MRI is the best approach for evaluation of spine metastases because its high soft-tissue contrast results in excellent sensitivity. The reported sensitivity of MRI varies from 83% to 100% and the estimated specificity is 92%, using biopsy or clinical follow-up as the index standard.^{13,14}

In developed countries using ACR criteria an important component of back pain management, the appropriateness of lumbar spine MR utilization has been studied. It was found that appropriateness of lumbar MR use varied from 12% to 56.7%. The author specifically proposed a restrict MR diagnosis criterion to minimize errors from evaluators' conceptual differences on MR findings.¹⁵

The present study reported that difficulties in walk and injury in back are better indicators for a lumbar MR study, as compared to simple back pain. This is consistent with previous studies that back pain without referred leg pain is a risk factor for inappropriate prescription of lumbar spine MR opposing to common view, however, raised duration of back pain, leg pain or walk problems was not related with greater chance of detecting potentially clinically significant findings on MR images.¹⁶

MRI is the method of choice for the evaluation of disk morphology because of the good sensitivity (60-100%) and specificity (43-97%) for disk herniation both protrusion and extrusion. It allows the physicians to diagnose infection early before bone destruction becomes visible on radiographic or

even CT. It shows the extent of the disease and soft-tissue involvement, especially epidural extent, it is considered critical before surgical intervention.¹⁷

Chronic low back pain is a condition clearly responsible for the pain without radiculopathy or anatomical abnormalities, could explain the identified association between back pain duration and negative MR findings. Referred leg pain and difficulties in walking are clear signs of nerve root compression or stenosis and hence the presence not duration is associated to significant MR findings.^{18,19}

MRI is the best approach for evaluation of spine metastases because of the presence of high soft-tissue contrast results in excellent sensitivity. It is considered to be the best technique to investigate marrow edema and soft tissues, including spinal cord and ligaments. The findings of MRI can be used to differentiate between malignant versus benign vertebral fractures. It is helpful in providing information regarding the underlying causes of LBP.²⁰

It has been found that MRI is the method of choice for evaluation of spinal disease, with sensitivity of 96% and specificity of 92%. It helps radiologists to diagnose the condition before it involves other parts. The reason is that MRI shows the extent of the disease and soft-tissue involvement, especially epidural extent; it is considered critical before surgical intervention.^{21,22}

CONCLUSION

MRI of lumbar spine is useful in the conditions of back pain. A proper understanding of the benefits and limitations of MRI in evaluating lumbar back pain may lead to better outcomes of a patient's radiologically matched clinical issues.

REFERENCES

- Cousins JP, Haughton VM. Magnetic resonance imaging of the spine. *J Am Acad Orthop Surg* 2009; 17(2):22–30 39.
- Preethi Ganesan, Abubacker Sulaiman F, Soorya Prakash, E.A Parthasarathy, Rajamani Anand, Ramya Kalaiarasan. Role of CT and MRI in spinal trauma. *International Journal of Contemporary Medicine Surgery and Radiology*. 2018; 3(2):11–14.
- Adams MA, Roughley PJ. What is intervertebral disc degeneration, and what causes it? *Spine* 2006; 31(1):2151–2161.
- Arun Prasad, Rajeev Anand, Anu Sarah Easo, Reshma Francis. Role of MRI in differentiating benign versus malignant ovarian lesions. *International Journal of Contemporary Medical Research* 2018; 5(4):4–7.
- Modic MT, Steinberg PM, Ross JS, et al. Degenerative disk disease: assessment of changes in vertebral body marrow with MR imaging. *Radiology* 1988; 166(5):193–199 42.
- Weishaupt D, Zanetti M, Hodler J, et al. Painful lumbar disk derangement: relevance of endplate abnormalities at MR imaging. *Radiology* 2001; 218(1):420–427.
- Amitha Kumari, Ananthalakshmi Paga. Comparative study of MRI staging vs figo staging of carcinoma cervix. *International Journal of Contemporary Medical Research* 2017; 4(5):1196–1198.
- Kalfas I, Wilberger J, Goldberg A, Prostko ER. Magnetic resonance imaging in acute spinal cord trauma. *Neurosurgery*. 1988; 23(3):295–9.
- Goldberg AL, Daffner RH, Schapiro RL. Imaging of acute spinal trauma: An evolving multi-modality approach. *ClinImag*. 1990; 14(3):11–6.
- Xiaobin Luo, Fubing Yang, Hui Yu, Lu Liu, Youlin Xu, Shangyi Xu. Clinical analysis of primary thoracic and lumbar intraspinal tumors misdiagnosed as lumbar intervertebral disc herniation: report of 19 cases. *International Journal of Contemporary Medical Research* 2019; 6(5):E16–E20.
- Malfair D, Beall DP. Imaging the degenerative diseases of the lumbar spine. *Magn Reson Imaging Clin N Am* 2007; 15(1):221–238.
- Mondita Borgohain, Pranjal Kumar Gogoi, Sujay Karmakar, Pradeep K. Multiple myeloma presenting as spinal cord compression: a report of five cases. *International Journal of Contemporary Medical Research* 2017; 4(4):837–839.
- Tins BJ, Cassar-Pullicino VN, Lalam RK. Magnetic resonance imaging of spinal infection. *Top Magn Reson Imaging* 2007; 18(2):213–222.
- Liedao Yu, Xuanwei Wang, Xiangjin Lin, Yue Wang. The use of lumbar spine magnetic resonance imaging in eastern china: appropriateness and related factors. *Plos ONE* 2016; 11(1): e0146369.
- Lu YW, Tian W, Liu YJ, Xiao B, Han X. A cross-sectional study on the prevalence and distribution of lumbar degenerative disease among adults in Beijing. *Chinese Journal of Orthopaedics* 2013; 33(3): 6. 17.
- Borenstein DG, O'Mara JW Jr, Boden SD, et al. The value of magnetic resonance imaging of the lumbar spine to predict low-back pain in asymptomatic subjects: a seven-year follow-up study. *J Bone Joint Surg Am* 2001; 83(5):1306–11.
- Sammer M, Jarvik J. Imaging of adults with low back pain in the primary care setting. In: Medina LS, Blackmore C, eds. *Evidence-based imaging: optimizing imaging in patient care*. New York, NY: Springer-Verlag, 2005:294–318.
- Emery DJ, Shojania KG, Forster AJ, Mojaverian N, Feasby TE. Overuse of magnetic resonance imaging. *JAMA Intern Med* 2013; 173(6): 823–5.
- Lehnert BE, Bree RL. Analysis of appropriateness of outpatient CT and MRI referred from primary care clinics at an academic medical center: how critical is the need for improved decision support? *J Am Coll Radiol* 2010; 7(1): 192–7.
- Kovacs FM, Arana E, Royuela A, Cabrera A, Casillas C, Pinero P, et al. Appropriateness of lumbar spine magnetic resonance imaging in Spain. *Eur J Radiol* 2013; 82(6): 1008–14.
- Bahman Roudsari, Jeffrey GG, Jarvik. Lumbar spine MRI for low back pain: Indications and Yield. *AJR* 2010; 195(1):550–559.
- Boden SD, McCowin PR, Davis DO, Dina TS, Mark AS, Wiesel S. Abnormal magnetic-resonance scans of the cervical spine in asymptomatic subjects. A prospective investigation. *J Bone Joint Surg Am* 1990; 72(2): 1178–84.

Source of Support: Nil; **Conflict of Interest:** None

Submitted: 09-05-2019; **Accepted:** 02-06-2019; **Published online:** 30-06-2019