

EVALUATION OF ROLE OF CT SCAN AND MRI IN DIAGNOSIS OF TUBERCULOSIS OF BRAIN AND SPINE

Radiodiagnosis

Dr. Pallavi Kar* 2nd Year Resident, Radiodiagnosis Department, SBKS Medical Institute & Research Centre, Sumandeep Vidyapeeth, Vadodara. *Corresponding Author

Dr. C. Raychaudhuri Professor And Head Of Department, Radiodiagnosis Department, SBKS Medical Institute & Research Centre, Sumandeep Vidyapeeth, Vadodara.

ABSTRACT

AIM: ROLE OF CT SCAN AND MRI IN DIAGNOSIS OF TUBERCULOSIS OF BRAIN AND SPINE.

BACKGROUND: Tuberculosis of the brain and spine is a very severe disease and causes increased rate of mortality and morbidity. Its diagnosis is a challenge for physicians worldwide. Patients of different age groups and having varied socio-economic status suffer from neurotuberculosis which need to be evaluated successfully to help the physician with further management of the condition.

METHOD: Patients referred to the radiology department with any kind of neurological symptoms, coincidental finding of neurotuberculosis or even those with already diagnosed cases of neurotuberculosis which needed follow up radiological investigations were evaluated with either CT or MRI or sometimes both (These were performed on 1.5 T Philips MRI and Siemens 16 Slice MDCT machine).

CONCLUSION: There is a wide spectrum of manifestations associated with intracranial and spinal tuberculosis. Tuberculous meningitis and Pott's spine were the commonest manifestations of intracranial and spinal tuberculosis respectively. MRI was more sensitive in the diagnosis of intracranial tuberculosis as compared to CT. CT had no significant role in the diagnosis of Spinal tuberculosis. Hence, MRI is the preferred choice of investigation while evaluating neurotuberculosis.

KEYWORDS

Neurotuberculosis, Tuberculoma, Tuberculous Abscesses, Intracranial Tuberculosis.

INTRODUCTION

Tuberculosis remains a major global problem and a public health issue of considerable magnitude. In recent times, there has been a resurgence of tuberculosis in both developing and developed countries.

The infection usually spreads through the hematogenous dissemination.[1]

The responsible organism is usually *Mycobacterium tuberculosis*. The *M. avium-intracellulare* complex rarely involves the CNS. *M. bovis*, a frequent pathogen in the past, is now rare.[2]

Tuberculous involvement of the central nervous system (CNS) is an important and serious type of extra-pulmonary involvement.

It has been estimated that approximately 10% of all patients with tuberculosis have CNS involvement.[3]

In developing countries CNS tuberculosis is a disease of younger age group, usually childhood and poor socioeconomic status is often the pre-disposing factor.

In developed countries, substance abuse, immunocompromised states and crowded conditions have contributed to a resurgence of tuberculosis.

Diagnosis is based on clinical features, cerebrospinal fluid changes, culture and immunological tissue tests and imaging characteristics.

Clinical features usually depend on the area being involved. Intracranial tuberculosis may manifest as a headache, fever or even giddiness, seizures, unconsciousness. Spinal tuberculosis usually manifests as back pain, deformity of the spine and rarely paraparesis.

The culture and immunological tests as well as evaluation of the cerebrospinal fluid are all time consuming methods of diagnosing neurotuberculosis, but they also give the confirmed diagnosis of the disease.

X-rays are usually the first investigation done for symptomatic patients, but they are helpful only in the late stages of the disease.

Recent advances in technology have allowed to utilize additional imaging modalities in the evaluation of central nervous system infections like PET, MR spectroscopy, however CT and MRI studies are generally the modalities of choice in the evaluation of the intracranial and spinal tuberculosis.

Since the advent of CT scanning and MRI, a significant decrease has occurred in the morbidity and mortality of patients with intracranial.[4]

However, MRI with gadolinium enhancement is more sensitive than CT scanning in determining the extent of meningeal and parenchymal abnormalities like tuberculomas, abscesses and infarctions in intracranial tuberculosis. It also depicts hydrocephalus readily.[5][6]

In spinal tuberculosis, CT scan is found to be very useful because of its ability to demonstrate bone destruction or focal osteopenia early in the course of the infection. Its ability to demonstrate soft tissue swelling and cellulitis, however, is disappointing. MRI has now become the study of choice for evaluating patients with spinal complaints. Its advantages include multiplanar capability, superior soft tissue contrast resolution, and a unique ability to detect end-plate, disc space and marrow changes. Moreover, it can demonstrate the subtle changes far earlier in the disease so that immediate management may be undertaken.[5]

Hence, even though CT imaging is helpful in the diagnosis of neurotuberculosis, MRI is the preferred choice for early diagnosis and CSF evaluation with culture and immunological tests for confirmation of the diagnosis.

MATERIALS AND METHODS

The study was carried out in the Department of Radiodiagnosis, S.B.K.S Medical Institute of Medical Sciences, Waghodia, Vadodara.

Study Design:

Type of the study: An observational, descriptive hospital based study.

Sample size: 65 patients.

Selection of Subject:

INCLUSION CRITERIA:

1. Only patients willing to participate in this study were included.
2. Patients referred to the radiology department for neurological symptoms, and found to have positive findings were included in this study.
3. All cases needing a follow up were included in this study.
4. All accidentally diagnosed cases of neurotuberculosis were also included.
5. All patients suffering from neurotuberculosis already diagnosed, treated and needing follow up were also included from this study

EXCLUSION CRITERIA:

1. All patients unwilling were excluded from this study.
2. Patients with claustrophobia.
3. Patients who are unable to cooperate for the procedure.

Study Tools :

These were performed on 1.5 T Philips MRI and Seimens 16 Slice MDCT machines.

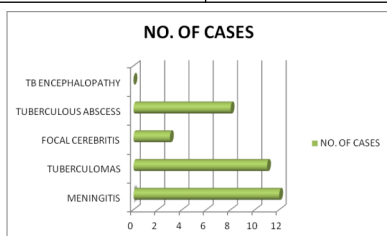
Study Protocol:

Routine blood investigations were documented in all patients:

1. Complete hemogram, which include Hb, total and differential count, Erythrocyte sedimentation rate.
2. Renal function test include blood urea and creatinine.
3. Random blood sugar estimation; fasting blood sugar and 2 hours post prandial if required.
4. Test for HIV and Hepatitis if required.

RESULTS**TABLE NO.1: TYPES OF INTRACRANIAL TUBERCULOSIS:**

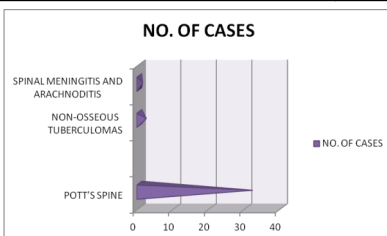
TYPE	NO. OF CASES
MENINGITIS	12
TUBERCULOMAS	11
FOCAL CEREBRITIS	3
TUBERCULOUS ABSCESS	8
TB ENCEPHALOPATHY	0



Here, patients with intracranial tuberculosis mainly presented with tuberculous meningitis and tuberculomas.

TABLE NO.2: TYPES OF SPINAL TUBERCULOSIS:

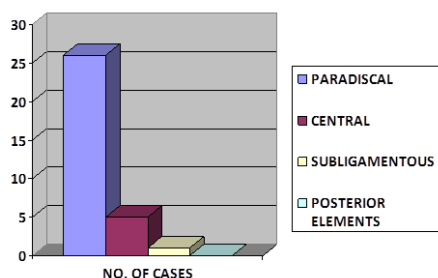
TYPE	NO. OF CASES
POTT'S SPINE	32
NON-OSSEOUS TUBERCULOMAS	2
SPINAL MENINGITIS AND ARACHNODITIS	1



As observed in the above table, most patients suffering from spinal infection presented with Pott's spine.

TABLE NO.3: TYPE OF LESION IN POTT'S SPINE:

TYPE OF LESION	NO. OF CASES
PARADISCAL	26
CENTRAL	5
SUBLIGAMENTOUS	1
POSTERIOR ELEMENTS	0



As observed in this table, most of the lesions were paradiscal with involvement of the articular discs. Very rarely, a subligamentous lesion was observed whereas lesions involving the posterior elements were not observed at all in this study.

TABLE NO.4: CT SCAN IN DIAGNOSIS OF NEUROTUBERCULOSIS:

LABORATORY CONFIRMED	CT SCAN DIAGNOSIS		TOTAL
	POSITIVE	NEGATIVE	
TB MENINGITIS	7	2	9
TB ABSCESS	0	1	1
TUBERCULOMAS	2	0	2
FOCAL CEREBRITIS	1	0	1

As observed in the above table, 13 cases of intracranial tuberculosis diagnosed on only CT scan and need further investigation to confirm the diagnosis.

TABLE NO. 5: MRI IN DIAGNOSIS OF INTRACRANIAL TUBERCULOSIS:

LABORATORY FINDINGS	MRI		TOTAL
	POSITIVE	NEGATIVE	
TUBERCULOUS MENINGITIS	2	0	2
TUBERCULOMAS	6	0	6
TUBERCULOUS ABSCESS	2	1	3
FOCAL CEREBRITIS	2	0	2

As observed in the above table, MRI can be confirmative in the diagnosis of intracranial tuberculosis. Further confirmation however can be obtained from different pathological tests.

TABLE NO. 5 :MRI IN DIAGNOSIS OF SPINAL TUBERCULOSIS:-

LABORATORY FINDINGS	MRI		TOTAL
	POSITIVE	NEGATIVE	
POTT'S SPINE	25	1	25
INTRAMEDULLARY TUBERCULOMA	2	0	2
SPINAL MENINGITIS	1	0	1

The above table proves MRI to be confirmative in spinal tuberculosis also.

TABLE NO.6: SENSITIVITY OF CT SCAN AND MRI IN DIAGNOSIS OF NEUROTUBERCULOSIS:

TYPE OF LESION	CT SCAN	MRI
INTRACRANIAL TUBERCULOSIS	76%	99%
SPINAL TUBERCULOSIS	-	99%

As proved in the above table, MRI is more sensitive than CT scan in the diagnosis of intracranial tuberculosis. MRI is also very sensitive in the diagnosis of spinal tuberculosis. However, CT plays no role in the diagnosis of spinal tuberculosis.

DISCUSSION**CT SCAN IN THE DIAGNOSIS OF INTRACRANIAL TUBERCULOSIS:**

13 patients in this study underwent CT scans, out of which 9 patients were diagnosed to have tuberculous meningitis, 2 tuberculomas, 1 case of tuberculous abscess and 1 case of focal cerebritis. The outcomes were compared with the pathological findings in the same patients. It was proved that CT scan alone carries a sensitivity of about 76% in the diagnosis of intracranial tuberculosis.

Selmali and colleagues studied that CT scan findings are typical of granulomatous meningitis with parenchymal involvement. Fungal infections and neurosarcoidosis may appear similar to CNS TB. At times, bacterial infections and metastatic disease also may mimic CNS TB. CSF analysis often helps in establishing the diagnosis.[6]

In another study Rajajee and colleagues studied the predictive value of CT scans in diagnosis of intracranial tuberculosis. Predictive value of CT scan in the diagnosis of intracranial tuberculomas have shown sensitivity at 100%, specificity at 85.7%, the positive predictive value was only 33%(confidence limits of 24-42%). The negative predictive

value 100%.The low positive predictive value for diagnosis of intracranial tuberculoma on CT alone indicates the need for confirming histological diagnosis.[7]

In an attempt to establish CT criteria for the diagnosis of CNS tuberculosis, Kumar et al. identified basal meningeal enhancement, ventriculomegaly, tuberculoma, and infarcts as characteristics to distinguish CNS tuberculosis from pyogenic meningitis and proposed that basal meningeal enhancement, tuberculoma, or both were 89% sensitive and 100% specific for TBM.[8]

MRI IN THE DIAGNOSIS OF INTRACRANIAL TUBERCULOSIS:

13 patients underwent MRI, out of which 2 cases were diagnosed as having tuberculous meningitis, 7 tuberculomas, 2 tuberculous abscesses and 2 focal cerebritis. All of the results of these patients were compared with the results of their pathological results and it was found that MRI has about 99% sensitivity in making accurate diagnosis of intracranial tuberculosis.

Gupta RK and colleagues described the different patterns of intracranial tuberculosis and proved that MRI is better able to detect the different features.[9]

In another study Jinkins and colleagues observed that contrast-enhanced MRI is generally considered to be superior to CT in detecting and assessing CNS tuberculosis.[10]

MRI IN THE DIAGNOSIS OF SPINAL TUBERCULOSIS:

27 patients underwent MRI for spinal evaluation, out of these, 25 patients were diagnosed to have Pott's spine, 2 patients had intramedullary tuberculomas and 1 had spinal meningitis. All of these results were compared to the pathological findings in these patients, and it was observed that MRI had a sensitivity of about 99% in the evaluation of the spinal tuberculosis.

A study carried out by Valk J, he too observed that MRI was preferred in the diagnosis of spinal tuberculosis as this technique allowed describing lesions of the spinal cord, meninges and epidural space more precisely.[11]

CONCLUSION

CT Scan and MRI scans have proved to be successful modalities in evaluating tuberculosis of the brain and the spine, but MRI results increased the physician's confidence in the diagnosis.

However there has to be a proper and careful correlation between clinical presentation and imaging results, a task that largely depends on the shoulders of the referring physician.

Tubercular meningitis and tuberculomas were the most common presentation of the intracranial tuberculosis. It was observed that there was not much significant difference between the two in the diagnosis of these two pathologies, however MRI has proved to be more accurate in diagnosing these lesions.

As other studies have shown that histopathological correlation with imaging is important in diagnosing intracranial tuberculosis, our study also shows the importance of this correlation and how it increases the accuracy of the diagnosis of intracranial tuberculosis.

The sensitivity of MRI was more in the diagnosis of spinal tuberculosis also as CT scan is not able to evaluate the extension of the lesion, the involvement of the articular discs and the compression of the spinal cord. However, calcifications and bone destructions were evaluated better on CT scan.

Contrast studies were all the important in confirming the diagnosis in all the different manifestations of neurotuberculosis.

Diffusion studies were also helpful in the evaluation of different intracranial manifestations of tuberculosis, but they were particularly important in the diagnosis of tubercular abscess.

CT and MRI studies proved very important in the evaluation of follow up cases of neurotuberculosis and this further helped the clinician to set the treatment according to the improvement.

Even though MRI is the investigation of choice in almost all the cases, CT is advantageous as it is easily available, more cost effective, less claustrophobic and less time consuming. Hence, while MRI is the preferred investigation for evaluation of intracranial and spinal tuberculosis, CT scan is the initial investigation of choice.

In the end, to optimize imaging of individual patients, it is also important to remember the contributions that can be made by plain films and ultrasounds.

REFERENCES

1. Okagaki H: Fundamentals of Neuropathology, ed 2, New York, Igaku-Shoin, 1989.
2. de Castro CC, Haselink JR: Tuberculosis, Neuroimaging Clin N Amer 1:119-139,1991.
3. Wood M, Anderson M(1998) Chronic meningitis. Neurological infections; major problems in Neurology, vol 16. (WB Saunders, Philadelphia), pp 169-248.
4. Rosenbaum ML, Hoff JT, Norman D, et al: Decreased mortality from brain abscesses since the advent of computerized tomography. J Neurosurg 49:658, 1978.
5. Charles F.Lanzieri, John R. Haaga, Robert C.Gilkeson :Magnetic Resonance Imaging of infections of the spine, CT and MR Imaging Of The Whole Body Vol 1: 805-813.
6. Semlali S, El Kharras A, Mahi M, Hsaini Y, Benameur M, Aziz N, et al. [Imaging features of CNS tuberculosis]. J Radiol. Feb 2008;89(2):209-20.
7. Rajajee S, Narayan PR. Immunonological spectrum of childhood tuberculous. J Trop Pediatr 1992; 21:490-6.
8. Kumar, R., N. Kohli, H. Thavnani, A. Kumar, and B. Sharma. 1996. Value of CT scan in the diagnosis of meningitis. Indian Pediatr. 33:465-468.
9. Gupta RK1, Jena A, Singh AK, Sharma A, Puri V, Gupta M, Role of magnetic resonance (MR) in the diagnosis and management of intracranial tuberculomas, Clin Radiol. 1990 Feb;41(2):120-7.
10. Jinkins, J. R., R. Gupta, K. H. Chang, and J. Rodriguez-Carbajal. 1995. MR imaging of central nervous system tuberculosis. Radiol. Clin. N. Am.
11. Valk J(1998) Gd-DTPA in MRI of spinal lesions. AJR Am J Radiol 150:1163-1168.